


The
British
Horse
Society

NO
PAIN?



CHECK AGAIN

An Equine Dental Health Project

A joint project in partnership with:



EDC
Equine Dental Clinic



CONTENTS

Introduction

Horses evolved to chew

Why regular dental checks are so important and who to contact

Clinical signs of dental problems

Is your horse trying to tell you something? Findings on examination

Dental care for the older horse

Equine dentistry - is there a link to performance?

What should happen at the dental examination?

How bad can it get?

What should I do now?

This guide and campaign is supported by:

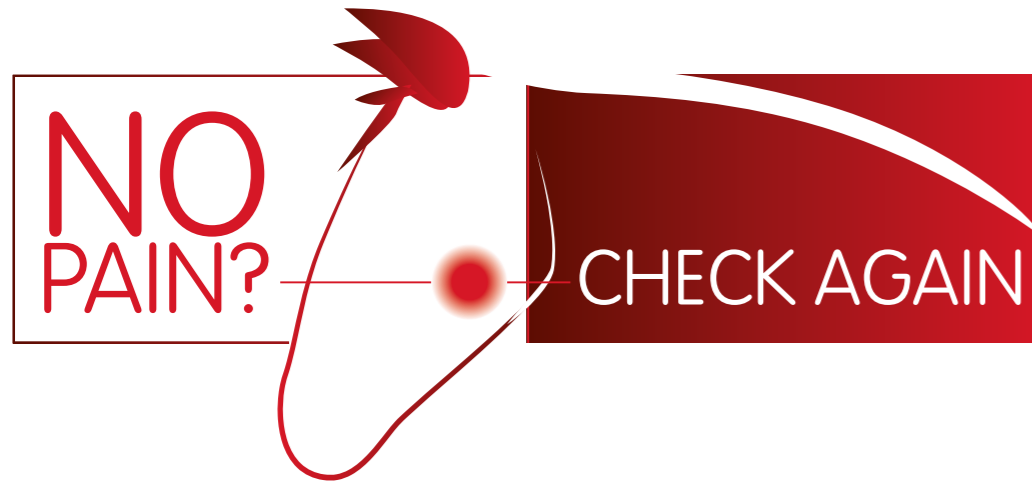


Introduction

In the past, equine dentistry has been a neglected area of veterinary research and practice. Thankfully over the last 20 years huge developments have led to a greater understanding of the problems horses experience and best practices developed for treatment. This is great news for our horses but there is still a huge area of concern. As horses are stoic animals they are cleverly able to hide their dental pain. Due to this, many horse owners don't realise that their horses could be suffering in silence. This is bad news as dental problems can seriously deteriorate unseen until the horse shows clinical

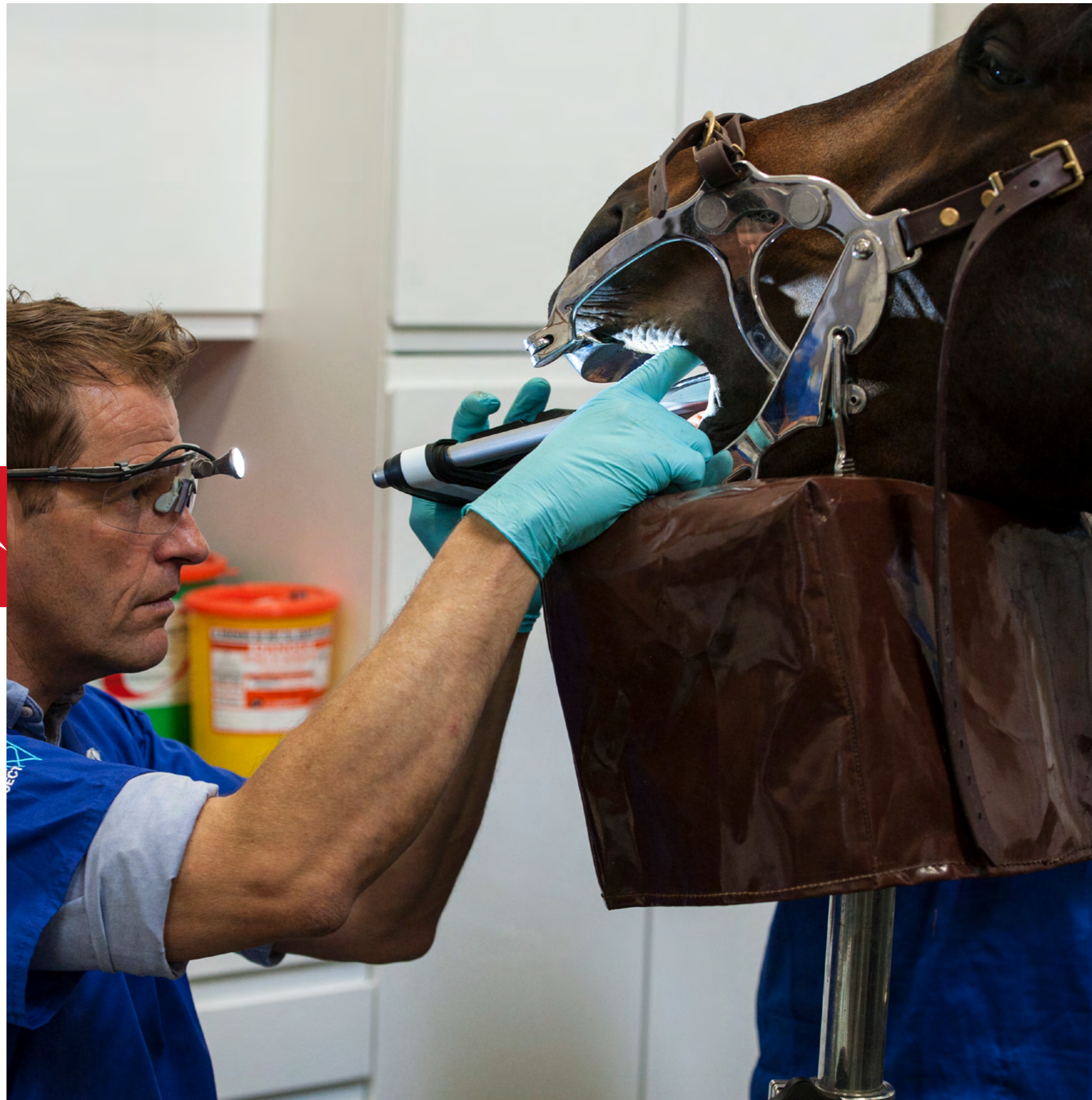signs. The scale of dental problems is quite phenomenal as recent studies have found that up to 70% of horses have undiagnosed dental problems. This is a real welfare concern for our horses and why dental checks every 6-12 months are so important to ensure any unidentified issues are treated as quickly as possible.

Many modern dental treatments are only possible if problems are identified before they become advanced. Just as in humans, early intervention is better than dealing with a dental catastrophe. No pain? Check again!



This guide has been produced in partnership with Chris Pearce, Director and founder of the Equine Dental Clinic. Chris, a veterinary surgeon, has considerable experience and qualifications in equine dentistry at all levels. Chris passed the first full European Diploma of Equine Dentistry examination in 2014 making him an officially recognised European Specialist with similar recognition from the Royal College of Veterinary Surgeons. Chris was also the first vet in the UK to pass the BAEDT dental technician's examination in 2001. He won the Petplan Vet of the Year award in 2011 in recognition for his efforts to improve equine welfare through dentistry treatments and education. He is involved with an array of veterinary and dental committees and travels the world to educate others and examine and treat horses. Chris is hugely passionate about improving horse dentistry and is continually concerned about the number

of horses he has to treat with difficult problems that could have been prevented. Chris said; "We see cases in our referral clinic and around the country every day with advanced severe dental problems which could have been helped often many years before. Horses will continue to eat 'come what may', it's in their nature. We need to shift our whole approach and understanding of dental diseases in horses to bring dentistry up to the standard our horses deserve – regular examinations, early treatments and preventative care – just like in humans. And, very importantly, protection from untrained and unqualified persons by proper regulation of dental care for our horses. I am delighted that the BHS is helping to educate horse owners and industry professionals through this campaign – horse welfare is not best served through ignoring or not appreciating dental problems; if there seems to be no pain – check again!"





HORSES EVOLVED TO CHEW

The horse has evolved to chew coarse grasses and rough forage for over 16 hours a day which equates to around 30,000 chews a day! So how does the horse do it?

Teeth

Adult male horses will have between 40-44 permanent teeth while a mare has between 36-40 teeth.

Twelve incisor teeth, located at the front of the horse's mouth, are the 'cutting' force. Their job is to grasp and tear the food, which can be easily seen when the horse grazes out in the field.

Twelve premolars and twelve molars, which are commonly known as the 'cheek teeth' are situated on both sides of the horse's lower and upper jaw. These teeth are specifically designed for chewing and grinding as they are wide, flat and have grooved surfaces. The premolars and molars are tightly lined up together which gives the appearance of one large chewing surface. This is known as the dental arcade.

The space between the incisor teeth and cheek teeth is known as the interdental space. Canine teeth, also known as 'tushes', grow a small way behind the incisor teeth. They are present in male horses and are believed to have originated for fighting purposes. About 25% of mares will have canines but in these instances the teeth are usually very small and don't serve a specific purpose.

The 'wolf tooth' is in fact the first premolar, which has reduced in size over millions of years to become almost non-existent and is no longer functional. It is usually located right in front of the first proper cheek tooth but may be placed a little in front of the cheek teeth or sometimes to the side.

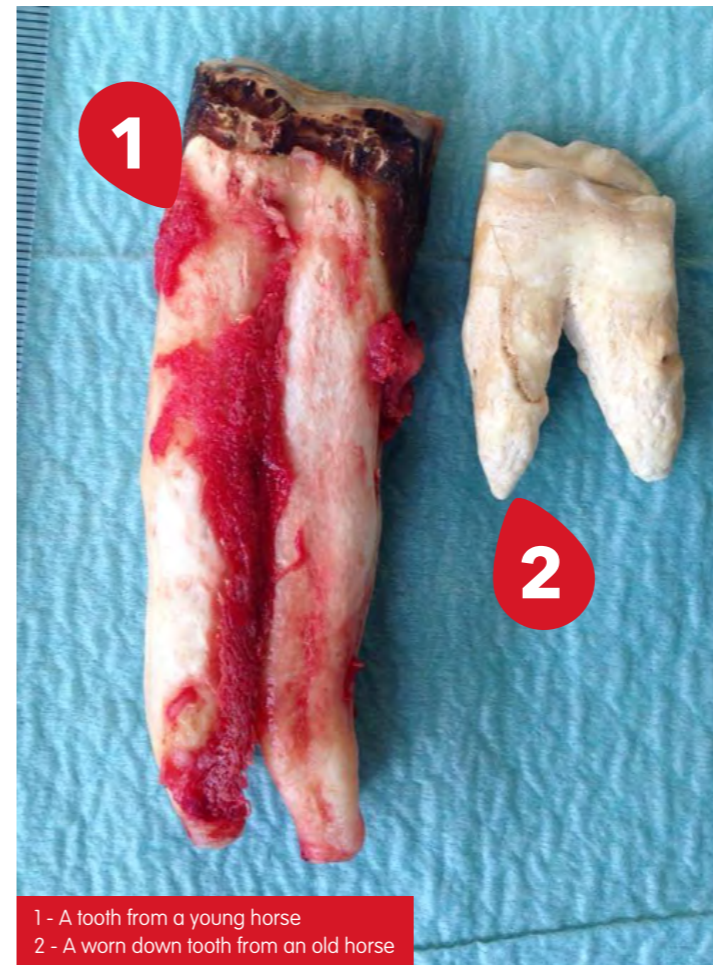
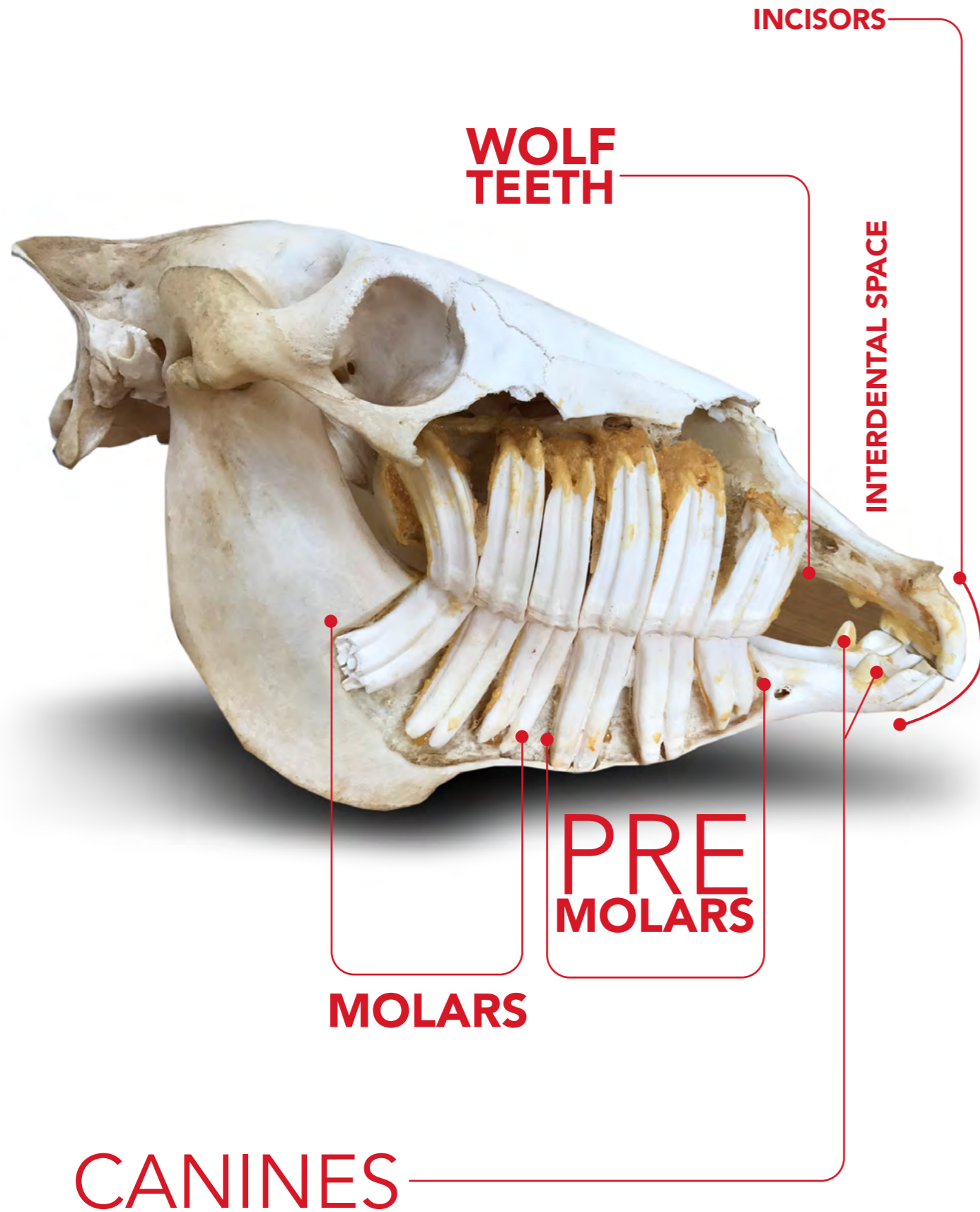
Sideways motion

When a horse chews its food, the movement of the jaw will work in a side-to-side, circular motion and not just in an up and down direction. The upper jaw of horses is slightly wider than the lower jaw. The horse will chew from the outside to the inside with the teeth of the lower jaw sliding along the upper teeth. A horse can choose which side of their mouth they want to chew on and in a healthy horse this effort will be shared evenly between both sides. As the horse chews, saliva is produced. This is mixed in with the chewed food (bolus) as it works its way from the premolars to the back molars in preparation to be swallowed.



If the horse has pain, it will choose to chew on the non-painful side which is likely to go unnoticed.

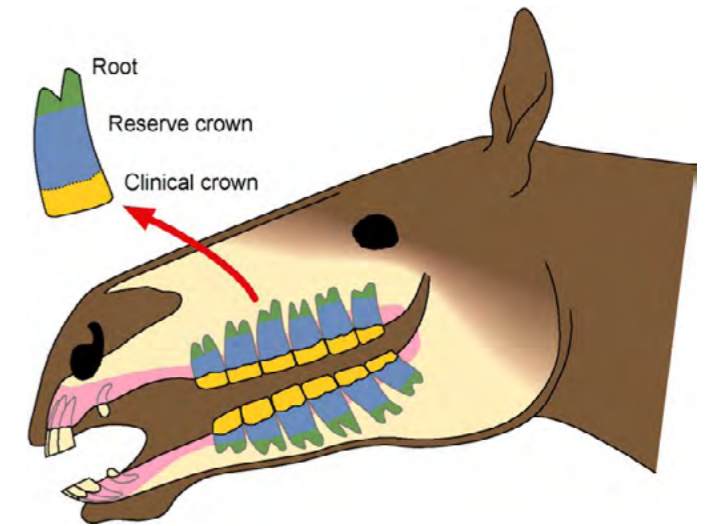
Skull from a young horse



1 - A tooth from a young horse
2 - A worn down tooth from an old horse

Continual wear

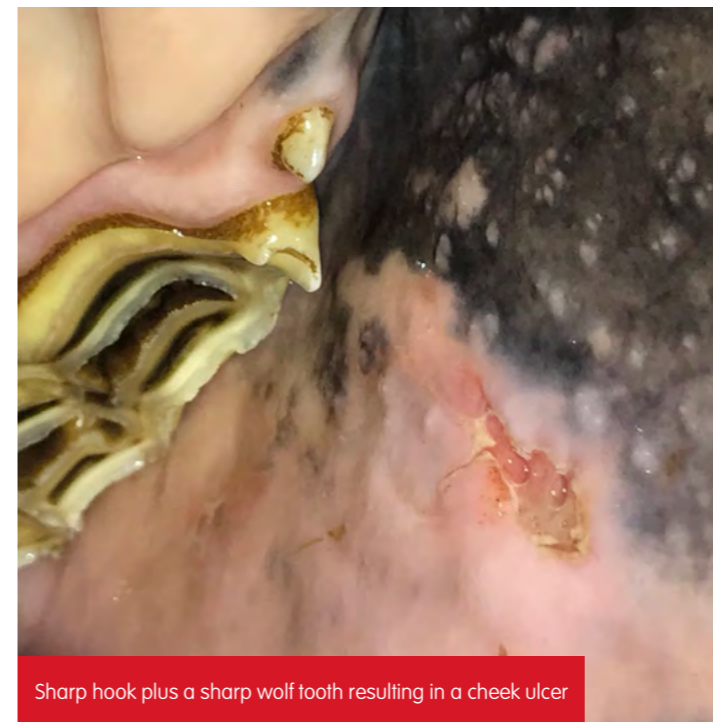
With all the chewing and grinding, the surface of the teeth will naturally wear away approximately 2-3mm every year. To compensate for this loss, horses' teeth develop and continually erupt as they wear (hypsodont). In the young horse, its permanent teeth are still largely buried beneath the gum line and therefore will slowly continue to erupt at the same rate as the tooth loss. The part of the tooth not erupted yet is known as the 'reserve crown'. As the horse continues to age the reserve crown gradually become shorter. When the horse reaches its mid to late twenties, there is no reserve crown left to erupt – the availability of tooth to grow effectively 'runs out'.



Modern management

Let's just think about this for a minute as this natural evolution of eating grass and rough forage for over 16 hours a day, 365 days a year, is often not the case for domesticated horses whose lifestyle often involves stabling, restricted diets and being fed processed feeds. Even though the horse is still chewing, the incisor teeth are not required to tear/cut the feed first which might lead to incisor overgrowth. In addition, the natural circular motion needed to chew hay, haylage or modern feeds, which are classed as 'softer feeds', isn't as great in comparison to coarse grass.

This altered circular motion means that the outer edges of the upper cheek teeth and the inner edge of the lower cheek teeth do not fully come into contact with each other (malocclusions) and the horse's natural ability to evenly wear down its teeth is reduced. Despite changes to the range of movement, the teeth will continue to erupt at the normal rate. Over time problems can develop including sharp enamel points, ramps, shear mouth and hooks, which if left untreated cause pain, soft tissue damage and ulceration. If there are missing teeth, broken teeth or displaced teeth then the subsequent overgrowths can be severe.



Sharp hook plus a sharp wolf tooth resulting in a cheek ulcer

Why regular dental checks are so important

Question

My horse is looking in great condition, happily eating, working well and doesn't have any physical signs of a problem so what's the point in spending more money and having my horse's teeth checked?

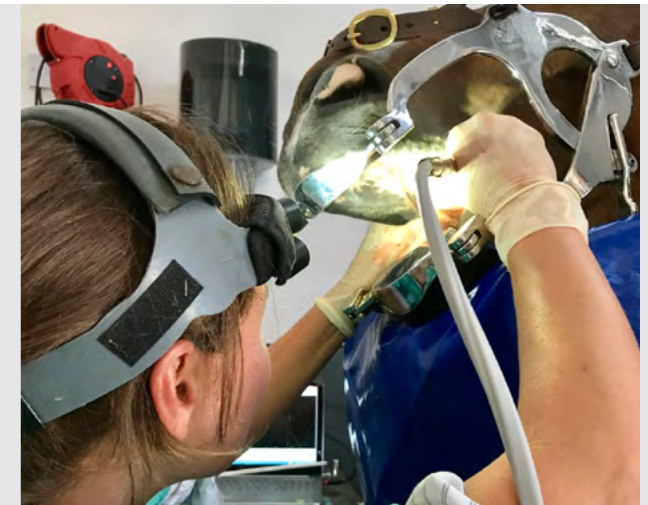Answer

The simple answer is that horses can hide their pain.

Horses have evolved as prey animals, and they do not easily display signs of dental pain. Left unchecked, dental problems can deteriorate until the horse reaches a point where they can no longer hide the problem. This can mean that the first outward signs you see are likely to be a result of mid-long term pain. Prevention is better than cure and it is important to maintain regular dental health checks for your horse. Keeping our horses healthy and performing to the best of their ability means ensuring that horses can eat and work pain-free and productively. Chewing and grinding feed is essential to your horse's survival!

Who should examine my horse's teeth?

- 1** A veterinary surgeon, ideally equine specific, trained in modern dentistry. In the cases of advanced procedures, your horse may be referred to a vet who specialises in equine dentistry.
- 2** A qualified equine dental technician (EDT) who is registered with the British Association of Equine Dental Technicians (BAEDT). To be registered with the BAEDT, EDT's must pass specific examinations, be fully insured and work within strict guidelines to ensure the horse's welfare and safety is never compromised. There may be instances when an EDT will have to request a veterinary surgeon to attend for example for sedation, or to refer to when more invasive treatment is required. To find an EDT in your area, visit the BAEDT website. Some vets are also members of the BAEDT.



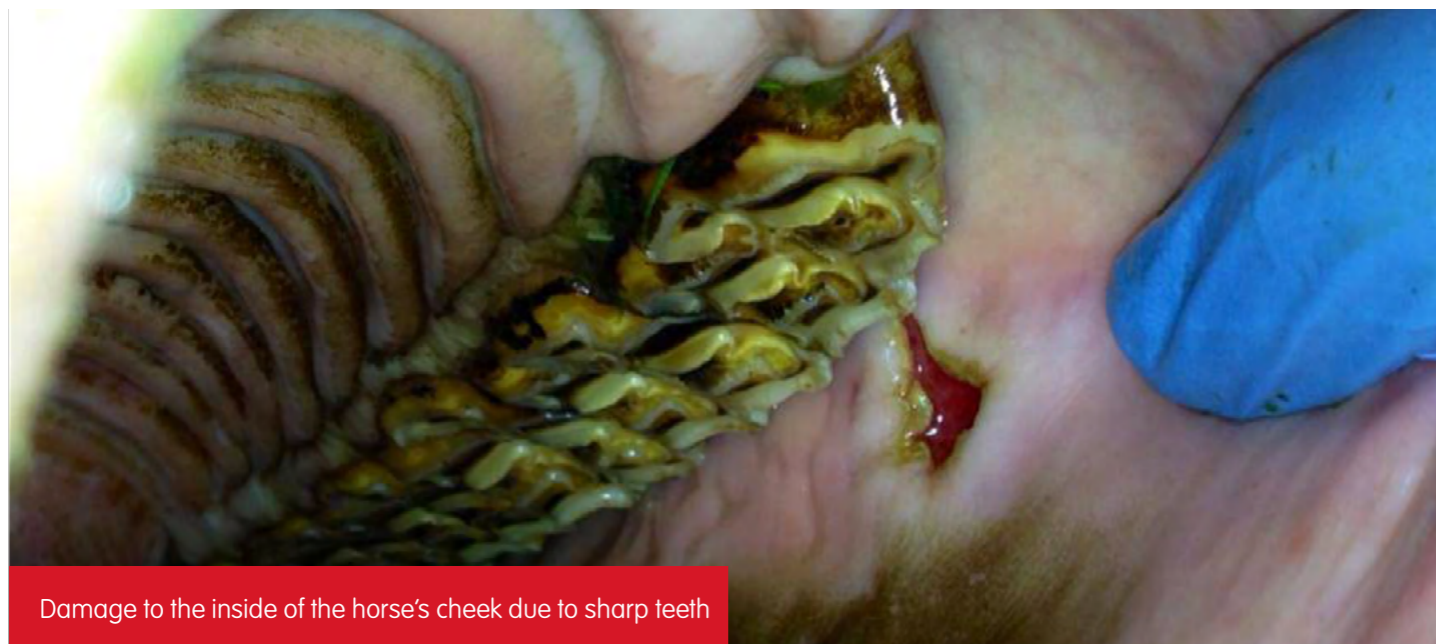Horse referred to an equine veterinary dental specialist

No pain? Check again!

Is your horse suffering in silence? The **painful** truth.

Recent studies have found that up to 70% of horses have undiagnosed dental problems. This is a real welfare concern for our horses. It is highly recommended that your horse's teeth are examined a minimum of once per year. This recommendation will vary for older horses or those that

have specific abnormalities. Like many health issues, early intervention is better than waiting for a dental catastrophe which is when the signs of a problem suddenly appear and may result in no other action other than having to remove the diseased tooth.



Damage to the inside of the horse's cheek due to sharp teeth



It is important to be aware that there are many 'equine dentists' who do not have sufficient qualifications. As a result serious problems could be missed or ineffective treatment given to your horse which could have implications in the future.

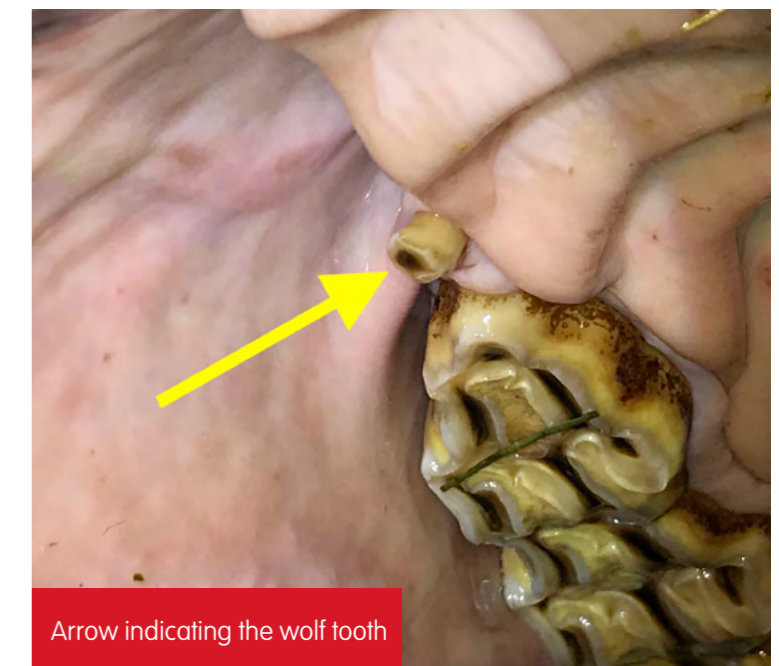
At what age should I start getting my horse's teeth checked?

Growing up ourselves we may have memories of visiting the dentist from a young age. This is important as any problems that arise as we get older are promptly dealt with. We should be applying the same process to our horses. Having their teeth checked a minimum of once a year from when they are a foal (to make sure the teeth are aligned and erupting correctly), will go a long way to ensuring they have the healthiest teeth leading into their older years. The prevalence of tooth and gum diseases such as periodontal disease (from food stuck in gaps between the teeth) can be reduced by simple treatments if found early enough at routine examinations.

It is especially important to have your horse's teeth checked before introducing the bit for the first time. The presence of any wolf teeth has the potential to cause interference and discomfort. It is important the horse has a pain-free experience otherwise they may become difficult to have a bridle put on if they associate this action as causing discomfort or pain.

If you have recently purchased a horse it is sensible to have their teeth checked as soon as possible. The history of the horse may be unknown to you and it is important to identify any problems as soon as possible.

In fact, any dental disorder can be missed when purchasing a horse and may have serious effects on performance or cause later medical problems. A complete thorough oral examination is extremely important.



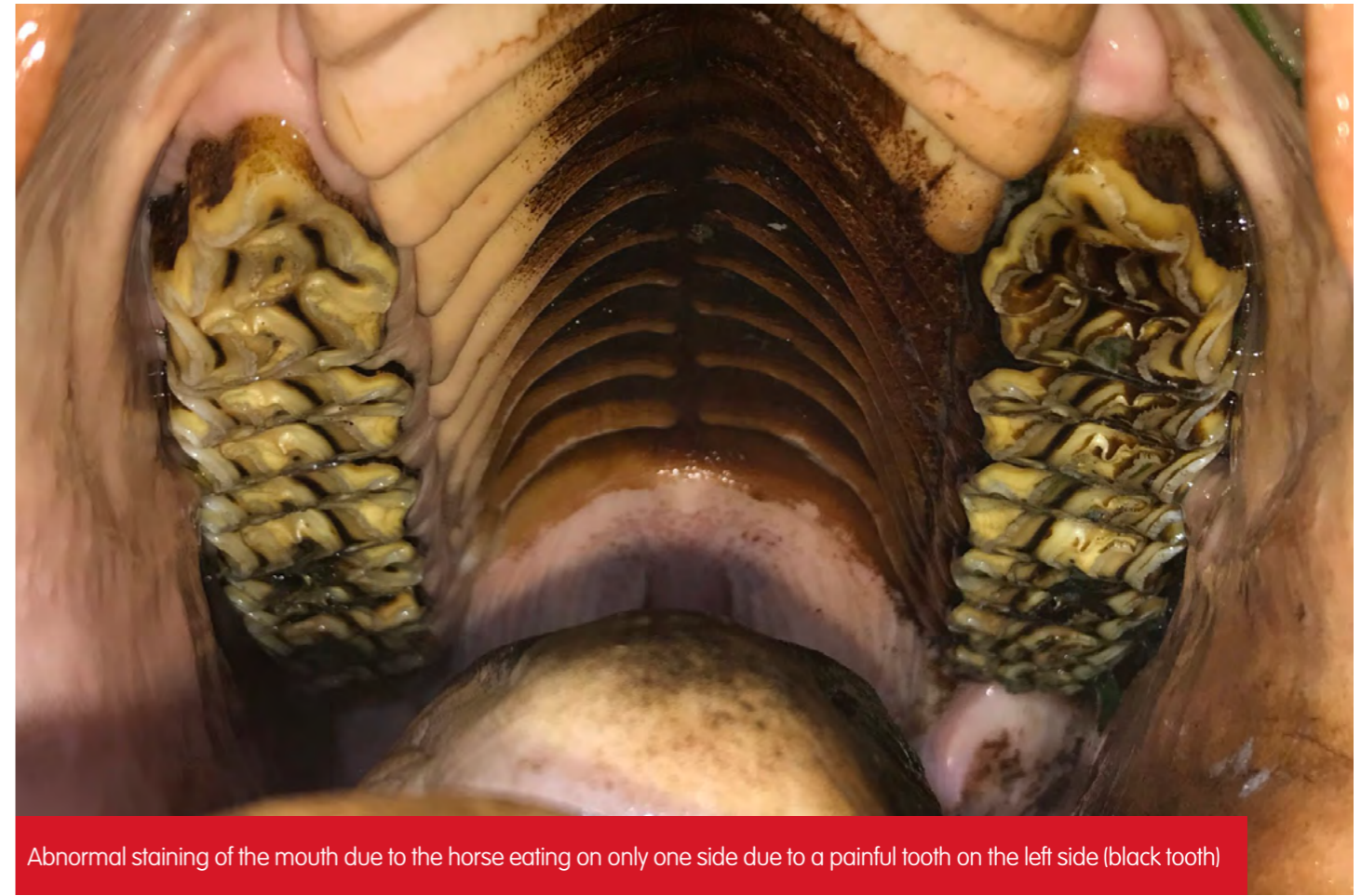Arrow indicating the wolf tooth



CLINICAL SIGNS OF DENTAL PROBLEMS

Horses are stoic animals, which mean they can endure pain for long periods of time without showing signs, especially with pain related to teeth. The early signs of dental problems are very subtle and may not be noticed by owners or carers at all.

Therefore, when horses eventually show outward signs of dental discomfort, the problem may have been developing for quite some time.



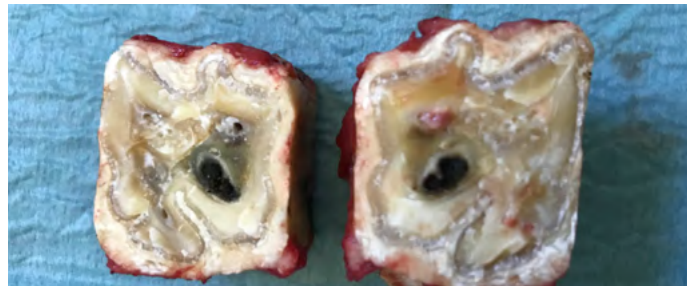
Abnormal staining of the mouth due to the horse eating on only one side due to a painful tooth on the left side (black tooth)



Very often the horse will not show any outward signs that anything is wrong.

Signs of dental problems can include:

- Resistance and evasion to the bit or bridle
- Changes in behaviour for example the horse becomes aggressive due to being in pain
- Change in behaviour when ridden for example head tilting, head tossing, mouth open and irregular head carriage
- Dangerous ridden behaviour for example rearing, bolting or bucking
- Facial swellings
- Refusing to eat
- Discharge and/or smell from one or both nostrils
- Excessive salivation
- Choke
- Weight loss
- Colic

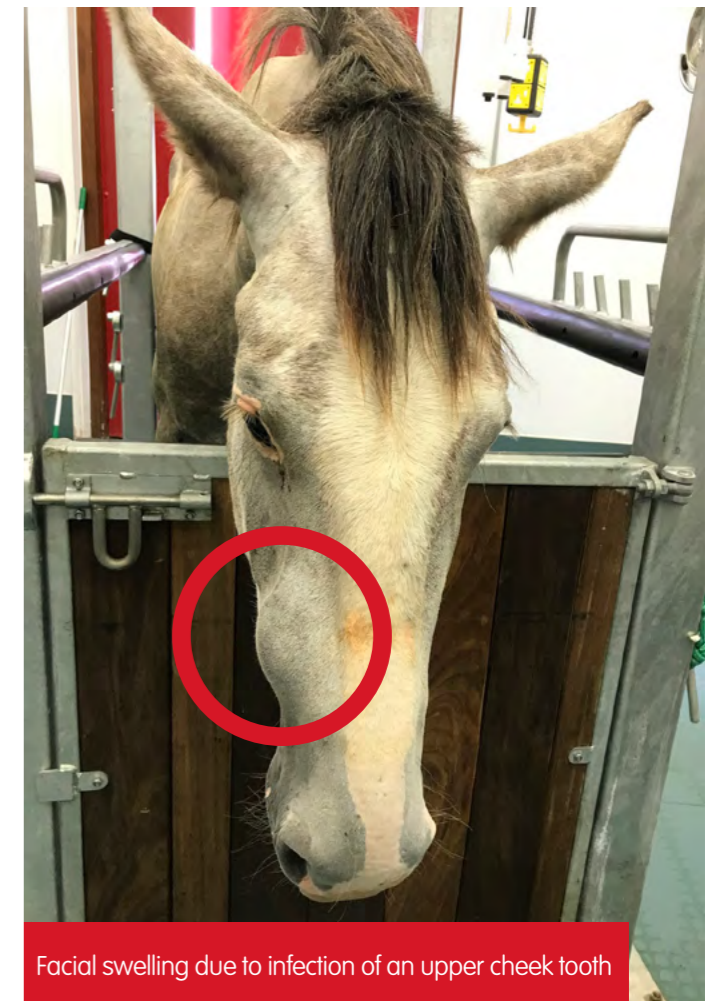

Slight yellow nasal discharge was the only sign that this horse had a diseased cheek tooth

- Inflammation of the gums
- Headshaking
- Depressive behaviour
- The horse only chews his feed on the same side of his jaw, every time
- Bad breath (halitosis) often caused by decaying tissue damaged by periodontal disease
- Long fibre or undigested food in droppings
- 'Pouching' of feed in the cheeks
- Quidding - partially chewed hay dropped
- Dropping hard feed

Signs related to ridden evasion or resistance can commonly be misinterpreted as biting or tack issues which then often results in a new bit or tighter noseband. The first thought should be to check if your horse is in pain. No pain? Check again! A thorough detailed examination is key, by someone trained to know what to look for. Such signs are also commonly due to back or other musculoskeletal disorders, that can also be due to dental problems.

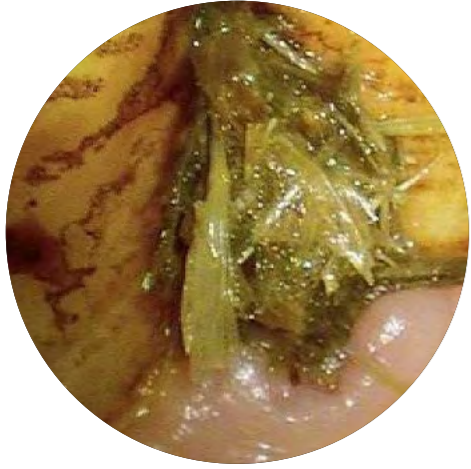Most of these signs will relate to conditions that have been present for some time, or a more advanced dental problem for example a fractured tooth. Amazingly, many horses show absolutely NO signs of even advanced dental disorders. Regular detailed examinations are very important to identify any developing problem.



Facial swelling due to infection of an upper cheek tooth

IS YOUR HORSE TRYING TO TELL YOU SOMETHING?

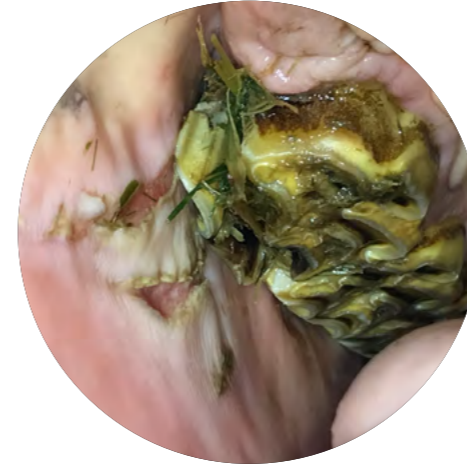
Findings on examination



Gum (periodontal) disease



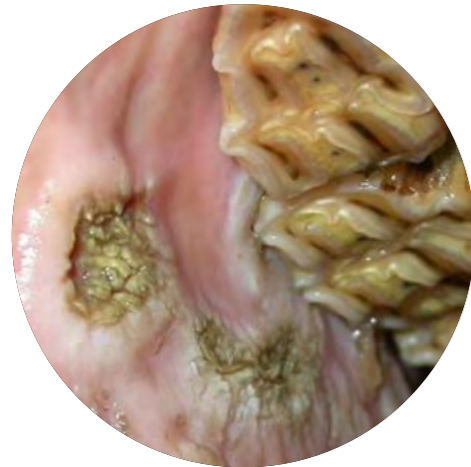Dental abscess



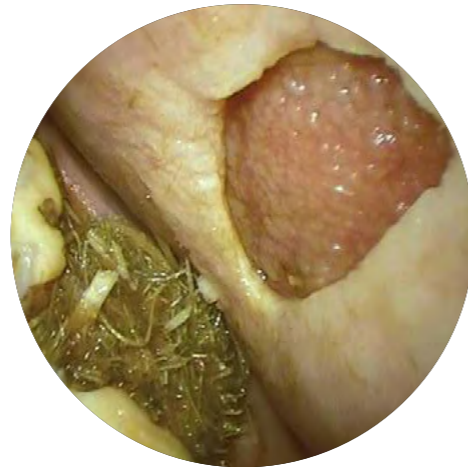Sores and cuts to the gum and/or tongue



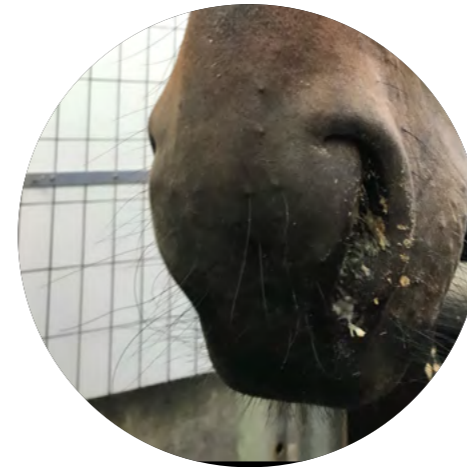Diseased and infected teeth



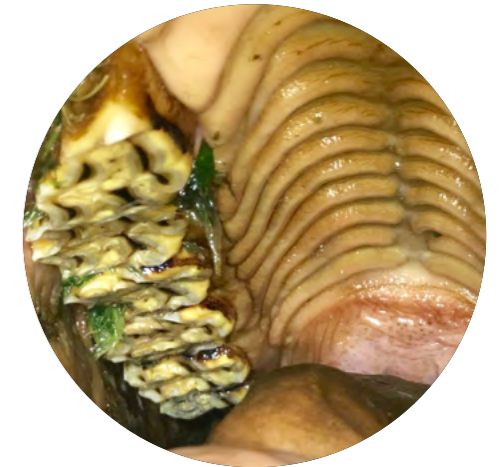Marked trauma caused by sharp edges of teeth



Ulcers

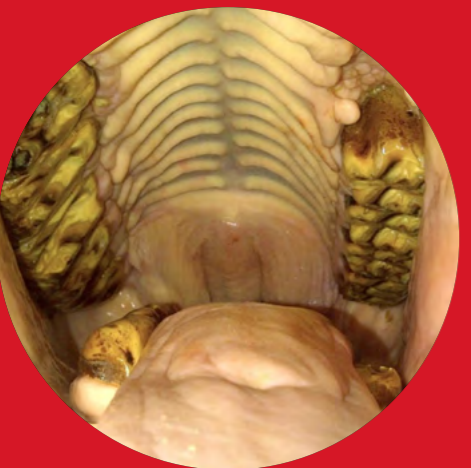

Sinusitis

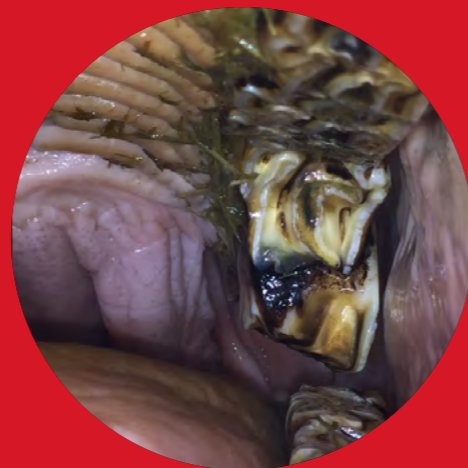

Bad breath
Often caused by trapped food or infection

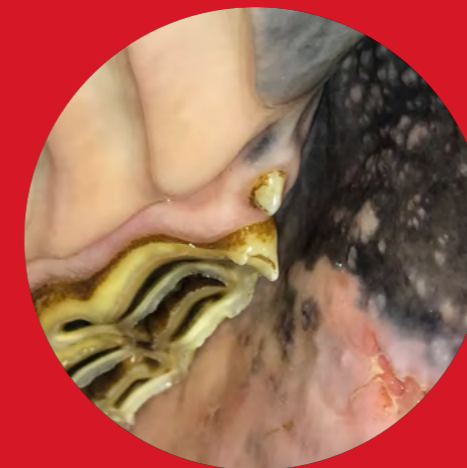Wear abnormalities



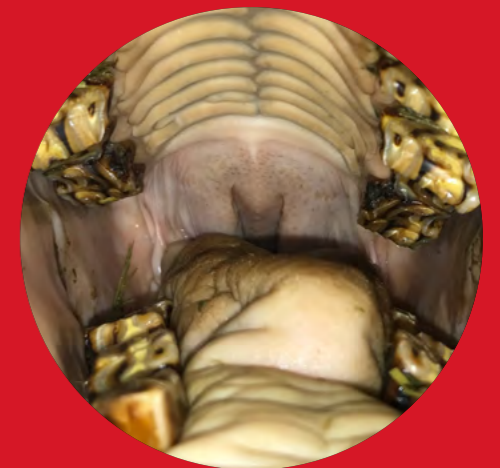Shear Mouth – caused by the horse eating on one side of its mouth causing steep angles



Step - large overgrowths due to missing and rotated teeth



Hooks



Waves - uneven wear of the molar arcades

Dental care for the older horse



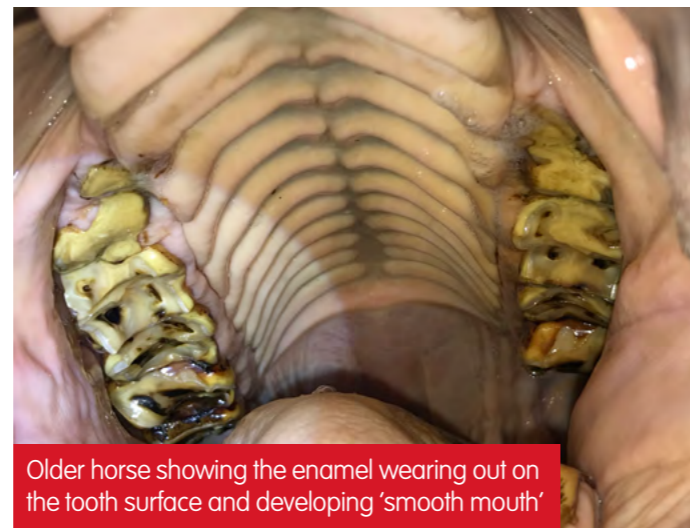With huge advances in veterinary science and nutrition the average life expectancy of a well-cared for horse or pony is increasing. By the age of approximately 25, the reserve crown (part of the tooth beneath the gum) will be very short. This increases the risk of periodontal disease, diseased roots, fractured or loose teeth. Older horses can suffer with a number of these problems at any one time, some of which may not be clearly visible to the owner. This is why it is so important for older horses to have dental checks every 6-12 months to ensure they are kept comfortable and pain-free.

The best care you can provide for your older horse's teeth is to ensure they receive regular dental examinations throughout their life.

Teeth Changes

The shape, length and condition of the teeth will change as the horse reaches its older years, which subject them to specific problems.

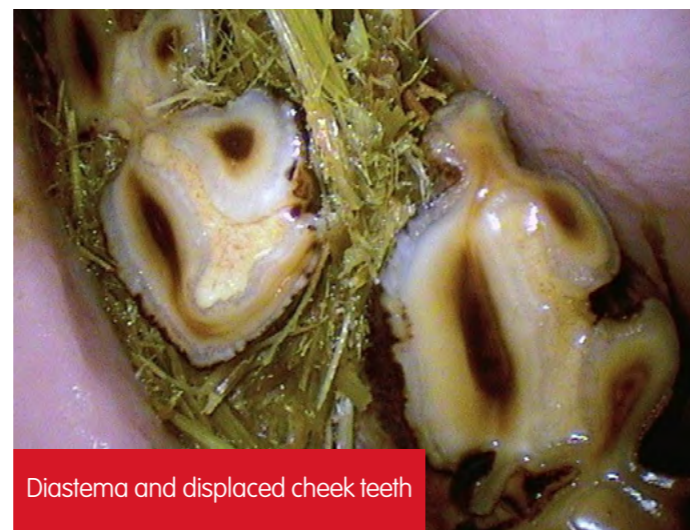As horses age, the enamel becomes thinner and subsequently less resistant to wear. Upper teeth gradually lose central rings of enamel, reducing wear resistance. In addition, teeth gradually become narrower towards the root. With these smaller and weaker teeth chewing becomes less efficient.



Older horse showing the enamel wearing out on the tooth surface and developing 'smooth mouth'

Gaps

As the teeth narrow, gaps (called 'diastema') of varying sizes naturally form between the teeth. Narrow gaps become a site for impacted food and a breeding ground for bacteria as the food rots. An acid is produced by the bacteria that decays surrounding teeth causing gum inflammation (gingivitis), foul-smelling breath, discomfort and infection. This may even progress to develop sinusitis if it involves the upper cheek teeth.



Diastema and displaced cheek teeth

You may be able to help your horse by using a soft tooth brush on a daily basis to remove any trapped food from between the incisor teeth. If you have difficulties with this, gently massage the stuck food to loosen and remove it. As this isn't the most pleasant job it is advisable to wear rubber/plastic gloves. Always ask your vet or qualified EDT for advice and don't get bitten!

Loose teeth

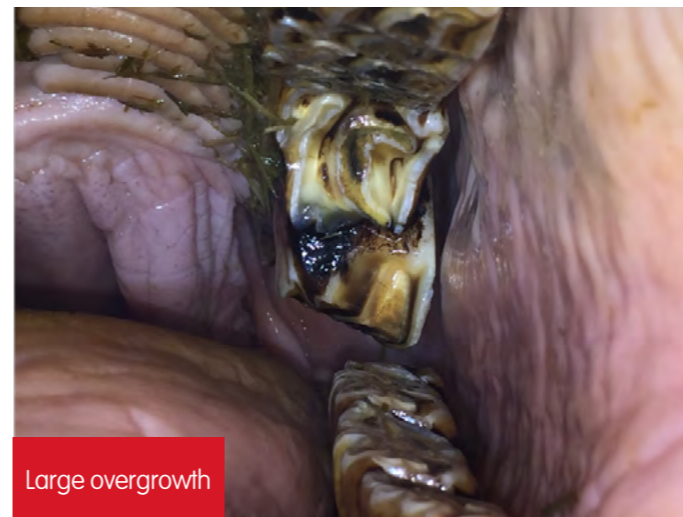As the horse enters its older years the risk of loose teeth increases, especially if the horse has severe gaps causing periodontal disease. Like humans, a loose tooth can be painful and will usually require extraction.

Grinding food is not so easy!

As the effectiveness of the teeth deteriorate, the older horse may begin to struggle grinding down certain foods such as grains, mixes or rough forages. As a result the horse may be at an increased risk of choke, colic and weight loss. The horse's diet will need to be carefully managed with softer, soaked, sloppy feeds to make it easier for the horse to chew. Hay replacers are widely available which are ideal for the older horse with poor dentition. Short chopped stalky forage should be avoided as it is difficult to grind effectively and may become trapped in-between the teeth as they get narrower causing gum disease. Soaked pelleted feeds are preferable to replace the fibre horses are not able to chew themselves. Soaking them can mean the teeth don't need to work very hard for the horse to get the nutrients it needs.

Sharp and overgrown teeth

As horses age, the tooth shape changes and the enamel becomes narrower, they may develop irregular sharp enamel points which may become painful and cause cheek or tongue ulceration. If the horse has not had regular dentistry through its early years, there may be some larger overgrowths that can cause serious ulcers and pain.



Large overgrowth

Dental Sinusitis

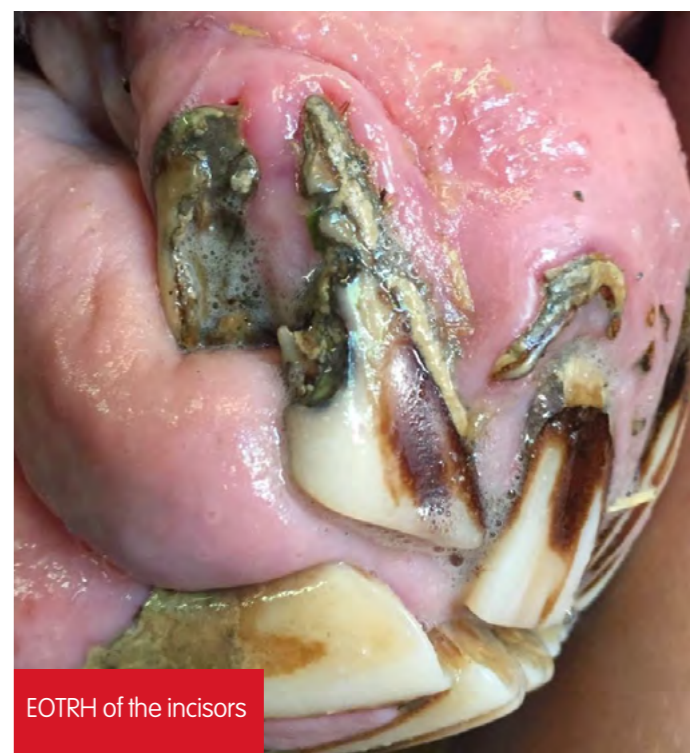Sinuses are air-filled cavities and it is thought they evolved to make the head lighter in weight, and to accommodate its large cheek teeth. Some of the upper cheek teeth roots are contained within the sinuses. Infection of the sinuses can be caused by a diseased tooth root. Older horses have larger sinuses (as the teeth are shorter) and can develop severe sinus infections.

Equine Odontoclastic Tooth Resorption and Hypercementosis (EOTRH)

EOTRH is a painful and progressive disease predominantly affecting the incisor and canine teeth in aged horses. It is believed to be an immune mediated disease and the teeth effectively start to be reabsorbed by cells from the horse's own body. As the teeth get absorbed, some teeth may start to develop excess cementum at the root ('hypercementosis') in an attempt to stabilise the tooth.

There are a wide range of clinical signs the horse with EOTRH will show including reddening of the gums (spots or larger areas), recession of the gums, plaque, bulbous (bulging) enlargement of the dental structures under the gums and loose, fractured or missing teeth.

Currently there is no treatment available for EOTRH and in serious cases the affected teeth are best removed. Such action may need serious consideration for the future management and quality of life for the horse depending on how many teeth are affected. However, horses do very well once the source of the chronic pain has been removed. Most owners report their horses are much brighter and happier after these diseased teeth are removed.



EOTRH of the incisors

Cushing's Disease

Equine Cushing's Disease (also known as pituitary pars intermedia dysfunction, or PPID) is a disease that involves the pituitary gland, located at the base of the brain which produces hormones in response to brain signals.

As well as variably causing coat changes, laminitis, increased drinking and urination, lethargy and increased sweating, Cushing's can also make dental diseases worse than they would be otherwise. Older horses with dental problems or sinus infections should be tested for Cushing's Disease – once the horse is receiving medication, the dental disease will be easier to treat.



EQUINE DENTISTRY

IS THERE A LINK TO

PERFORMANCE?

When a horse is suspected of performing below the expected standard, the most common descriptions from riders, trainers or owners as to the cause are often the only outward signs that are observable for example a swollen knee, a sore back, a subtle gait abnormality or 'something is just not right'. Many times these observable findings will turn out to be the cause of the problem, however in a lot of other cases these are either not present, or are not the cause of the primary problem.

Pain caused by dental disorders is a significant cause of poor performance in horses but it can be easily overlooked; it will not necessarily be associated with an obvious outwardly apparent problem, or even one easily viewed by diagnostic imaging techniques, at least in the early stages. Often when a cause is not found, it is often blamed on 'undiagnosed pathology'. However, a common place to find 'undiagnosed pathology' will be in the mouth.

Research has shown that horses respond to pain in the following ways:

- Head shaking
- Quiet behaviour
- Aggressive behaviour
- Abnormal gait, posture, balance
- Poor performance

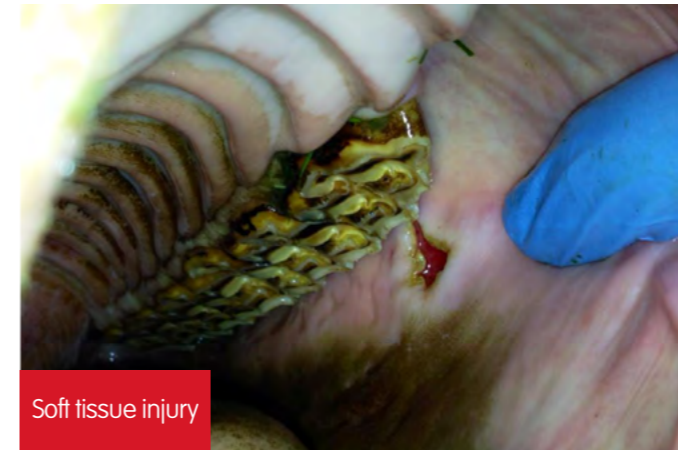

Pain may persist long after the pain-producing stimulus has been removed. It can result in a prolonged pain that may even be considered a disease in itself, often termed 'neuropathic pain'.

Which dental disorders do we need to look out for?

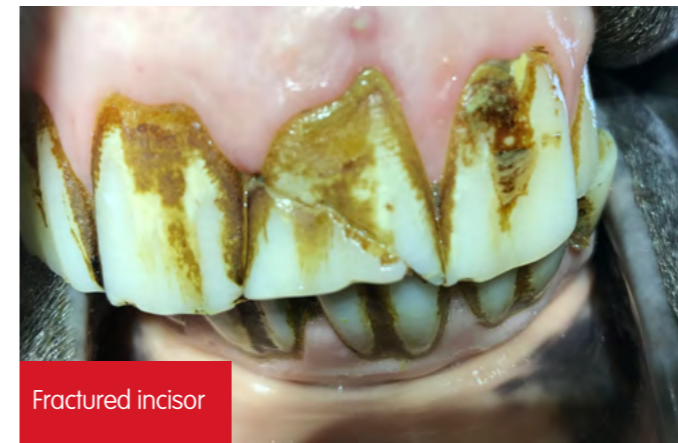The main disorders likely to result in pain and therefore potential performance, gait and balance disorders are:

- Soft tissue injuries – from sharp enamel points of cheek teeth, injuries to the 'bars' of the lower jaw from the bit



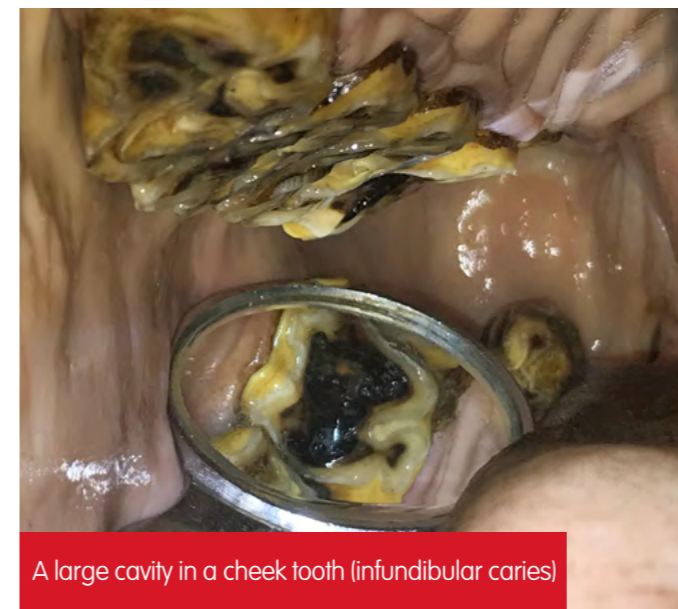Soft tissue injury

- Dental pulpitis (inflammation inside the tooth)
- Cheek tooth non-septic pulpitis (pulp inflammation)
- Cheek tooth septic pulpitis (infection, often leading to a tooth root abscess)
- Dental trauma for example fractured incisors



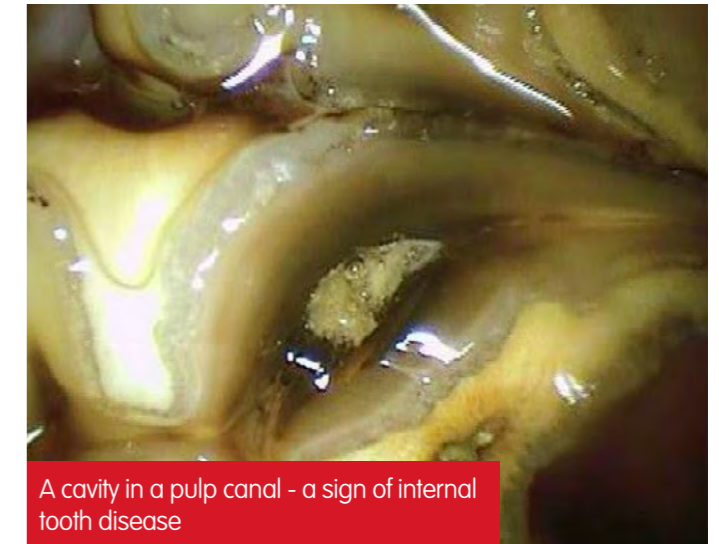
Fractured incisor

- Deep infundibular caries (central decay) leading to dentine and/or pulp inflammation



A large cavity in a cheek tooth (infundibular caries)

- Diastema and periodontal disease (food impacted between the teeth)
- Dentine sensitivity from cracks, partial fractures
- Dentine and possibly pulp exposure and bit contact (for example from 'bit-seats')



A cavity in a pulp canal - a sign of internal tooth disease

Abscesses, or root disease of the cheek teeth furthest forwards may cause externally visible facial swellings. For the teeth further back, the swelling may develop internally within the sinus, or nasal passages, restricting airflow. Cold air passing over such a swelling at exercise could easily cause marked discomfort. The dental pulp has a high capacity for repair and the body's own defence mechanisms can often resolve early problems without any external signs. If the disease overwhelms the local defences, it may not be obvious that a problem exists until days, weeks or even years later.

Nosebands

There are concerns that tight nosebands can potentially cause added discomfort to those horses suffering with an underlying dental problem.

Early diagnosis

It is very important to diagnose and treat dental disease at the earliest stage possible. Modern techniques using close-up video imaging of the teeth on a regular basis and shifting the emphasis from just routine rasping to regular clinical examinations will allow early diagnosis in many cases. A thorough dental investigation should also be performed in any case of suspected poor performance, with acceptance that early pulpitis (inflammation inside the tooth) may not show any diagnosable changes, only pain.

To really help horses' performance we should be concentrating on elimination of development of dental pain by clinical examinations and early intervention before severe chronic disease and pain syndromes develop.

What should happen at the dental visit?

Your horse is best stabled and relaxed for a dental visit. Arrive early and make sure the stable is clean and tidy. Don't give a feed a short time before the visit – just like you wouldn't eat just before going to the dentist! The vet or EDT will need water, preferably warm water is beneficial in the winter. The routine for the procedure is normally as follows:



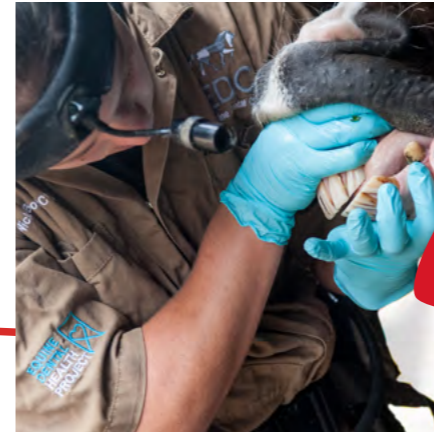1

Your vet / EDT will meet you and your horse and ask some questions including age, veterinary and dental history, if there are any problems, ridden performance and temperament. Your horse should be vaccinated for tetanus. The details should be filled in on a chart, either paper or electronic (for example on a tablet).



2

A little sedative may be given. Do not be concerned about this or feel this is somehow wrong or unusual. Dental examinations, just like we would expect are not always comfortable – especially if pain is present. Instruments used for examination may be sharp and potentially dangerous. Your horse will not want painful areas touched or examined and they can easily be missed. EDTs cannot legally sedate, and will have to proceed without. If necessary, a vet may have to be called as well.




3

The whole horse is checked, followed by a close inspection of the head. The incisors are examined, with palpation of the soft tissues between the incisors and cheek teeth.



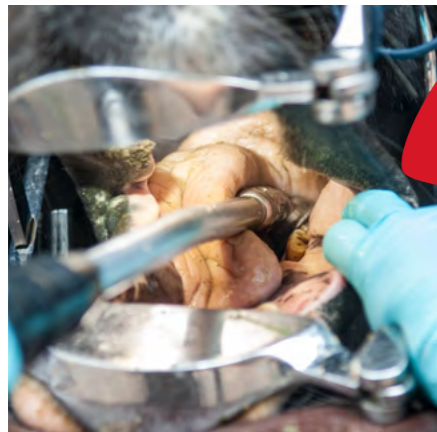4

A mouth speculum ('gag') is placed, and the mouth opened. The mouth is washed out thoroughly. The head may be placed on a head-stand.



5

A thorough examination is carried out – looking with a bright head light, palpating all the structures and recording the findings on the chart. A dental mirror should always be used. Dental picks and probes are also used to check for gaps, cavities and other diseases. Findings are recorded on the chart and discussed with the owner at the end of the examination.




6

Treatment of sharp points, focal overgrowths of individual teeth and general uneven wear is performed using either hand rasps or motorised instruments. Special training is always required for motorised instruments, but when used by qualified people* they are very safe and efficient.
*Visit www.baedt.com/legislation_5355.html for further details.



7

The mouth is rinsed and examined again. Further rasping may be performed.



8

Re-checking the incisors.



9

Discussion with owner and carer.

The benefits of regular dental checks are:

To keep your horse eating with maximum efficiency

Early intervention is better than dealing with a dental catastrophe – studies show long term problems are harder to treat

To ensure your horse is kept pain-free - there may be NO signs

Prevent the likelihood of tooth loss and other dental problems in older age – horses are living longer – they need good teeth

Avoid biting problems, especially when introducing the bit to a horse for the first time

To ensure your horse is working to their optimum ability

The best care you can provide for your horse's teeth is to ensure they receive regular dental examinations throughout their life



The
British
Horse
Society

This document has been produced with the collaboration of Chris Pearce MRCVS and the team at Equine Dental Clinic Ltd.
www.equinedentalclinic.co.uk

Images have been supplied by Chris Pearce MRCVS and remain the property of EDC Ltd

Are you a BHS Member?

Your membership will ensure that we can help support even more horse owners and horses.
To become a BHS member call 02476 840506

www.bhs.org.uk/teeth

